

OPEN

Chronic Exertional Compartment Syndrome Caused by Functional Venous Outflow Obstruction

Joseph C. McGinley, MD, PhD,*† Trey A. Thompson,‡ Shawn Ficken, PA-C,§ and Jessica White, RN§

Abstract

Objective: Investigate the theory that chronic exertional compartment syndrome (CECS) results from venous outflow obstruction due to functional muscular compression. Chronic exertional compartment syndrome occurs when increased pressure within a muscle compartment produces pain and/or neurologic symptoms. The exact etiology of CECS is unknown, leading to inconsistent diagnostic and treatment plans. **Study Design:** Retrospective case series. **Setting:** Private practice and sports medicine. **Patients:** Two hundred eighty-four patients with exercise-induced lower leg pain. Twenty-two patients lost to follow-up. **Interventions:** Leg vasculature was evaluated using stress computed tomography angiography (CTA) and MVP Flex to identify areas of functional venous compression. All patients then underwent targeted botulinum toxin treatment. Posttreatment follow-up imaging was performed using stress CTA in 197 patients. **Main Outcome Measures:** Presence of functional venous compression on stress CTA. Symptom reduction and normalization of venous flow after targeted botulinum toxin injections. **Results:** Baseline imaging demonstrated CECS and functional venous obstruction with replication of symptoms in 260 of 284 patients [91.5% ± 3.2% (95% CI)]. Four weeks after treatment, 227 of 284 patients [79.9% ± 4.7% (95% CI)] described reduced/resolved symptoms with activity. One hundred fifty-five of the 197 patients [78.7% ± 5.7% (95% CI)] reimaged with stress CTA demonstrated resolved/reduced venous outflow obstruction. Twenty-two patients were lost to follow-up, and 35 patients had persistent symptoms. **Conclusion:** Chronic exertional compartment syndrome results from venous outflow obstruction due to functional muscular compression. Understanding the cause of CECS will allow the development of more precise and successful treatment plans. Based on our findings, treatment should be directed at the sites of venous compression.

Key Words: chronic exertional compartment syndrome, calf pain, fasciotomy, venous outflow obstruction, popliteal artery entrapment syndrome

(*Clin J Sport Med* 2021;00:1–6)

INTRODUCTION

The calf is anatomically divided into 4 muscle compartments by strong fascial layers. Symptoms of chronic exertional compartment syndrome (CECS) result when pressure increases within specific muscle compartments during activity producing severe pain and, in some cases, neurologic dysfunction.^{1–3} The exact etiology of CECS has not been clearly identified, but magnetic resonance imaging (MRI) has demonstrated edema within the affected compartments after exercise.^{4,5} It has been postulated that increased blood flow with exercise, along with muscle hypertrophy, overcomes the ability of the fascia to accommodate the increased volume.^{6,7} This transient physiology results in elevated pressures in specific compartments. Pressure elevation in a closed compartment subsequently reduces blood flow resulting in ischemia and pain in the involved muscles. Treatment options

for CECS are limited. Discontinuation of the sports and activities aggravating the symptoms is often recommended first. If the patient requires further treatment, surgery to release or excise the fascial layers is often performed.⁸

Chronic exertional compartment syndrome typically involves the lower leg; however, there have been cases involving the proximal leg, foot, and upper extremity.⁹ The prevalence of CECS is not fully known as patients often opt for conservative therapy and do not undergo invasive surgery.^{2,10} A recent study by Waterman et al¹¹ evaluated risk factors associated with CECS in a military population demonstrating an incidence rate of 0.49 cases per 1000 person-years. Symptoms are bilateral in 80%–95% of patients.^{1,12} Diagnosis of CECS typically involves a detailed history and compartment pressure measurements both at rest and after an exercise protocol. Symptoms often begin as a dull ache that progresses as exercise continues. The pain can become debilitating as ischemia develops within the muscles. Pain typically resolves with cessation of the activity.

Treatment of CECS is limited. The most successful therapy is cessation of the causative activity. However, this option is often not tolerated well and definitive treatment with fasciotomy and/or fasciectomy pursued. Outcomes after fasciotomy vary with reports suggesting an overall success of approximately 66%.^{13,14} Complications from surgery can be debilitating and include scar pain, nerve damage, infection, and recurrence of CECS as scar forms a pseudo compartment. Complication rates vary between 4% and 13% with

From the *The McGinley Clinic, Casper, WY; †Department of Radiology, University of Washington, Seattle, Washington; ‡University of Washington School of Medicine, Seattle, Washington; and §Casper Medical Imaging, Casper, Wyoming.

Conflicts of Interest: Patent, Ownership—MVP Flex, Patent—MVP Treatment

Corresponding Author: Joseph C. McGinley, MD, PhD, The McGinley Clinic, 234 E, 1st St, Casper, WY 82601 (mcginley@mcginleyclinic.com).

Copyright © 2021 The Author(s). Published by Wolters Kluwer Health, Inc. This is an open-access article distributed under the terms of the Creative Commons Attribution-Non Commercial-No Derivatives License 4.0 (CCBY-NC-ND), where it is permissible to download and share the work provided it is properly cited. The work cannot be changed in any way or used commercially without permission from the journal.

<http://dx.doi.org/10.1097/JSM.0000000000000929>

reoccurrence of symptoms reported in up to 36%.^{13,15–18} Recurrence rates are likely higher when releasing multiple compartments.^{13,19} Approximately 10% of patients undergo a second revision surgery. Inconsistencies in diagnosis and variable outcomes are likely due to a lack of understanding of the cause of CECS. Identifying the etiology of CECS may direct treatment to the problem, rather than the symptoms.

The purpose of this study was to characterize the pathophysiology of CECS. We investigated the hypothesis that CECS is a functional pathology resulting from transient venous outflow obstruction caused by dynamic muscular compression. With exercise, there is increased arterial flow to the lower legs. As the intensity of exercise increases, hypertrophied leg muscles compress the veins draining the calf compartments. As the inequality in flow persists between the arterial and venous system, edema in the muscles develop and pressure increases in the affected compartments. The pressure elevation in a fixed muscle compartment produces the symptoms associated with CECS. By identifying the underlying etiology of CECS, treatment can be directed at the site of abnormality.

METHODS

This research was approved by our institutional review board.

Two hundred eighty-four patients [mean age: 27.3 ± 1.3 (95% CI), age range: 16 to 77, 187 female patients and 97 male patients] with exertional lower leg pain were evaluated in this retrospective study (Table 1). The diagnosis of CECS was confirmed through a thorough history, physical examination, and lower-extremity MRI at rest and after exertion. Alternative causes of exercise-induced lower leg pain were eliminated, including stress reaction, stress fracture, medial tibial stress syndrome, soft tissue injury, myopathy, and muscle hernia. The patients' histories were evaluated and questions included time of symptom onset relative to activity, time of symptom resolution after cessation of activity, worsening of symptoms, chronicity of symptoms, recent injuries, presence of neurologic symptoms, discoloration of the toes, focal bone pain, or previous surgery. A thorough physical examination was performed. Key components of the examination included replication of symptoms during plantar flexion against resistance and evaluation of arterial pulse with stress positioning. The presence of CECS was then confirmed with preexercise and postexercise MRI using a previously reported technique.⁴ Resting MRI scans of the lower legs were obtained. The patient then exercised on a treadmill with increasing speed for at least 5 minutes (range 5-15 minutes) until moderate CECS symptoms were produced. A repeat MRI was then performed immediately after this exercise. Positive diagnosis of CECS was determined by evaluating the T2 signal intensity ratio to assess for the development of intracompartmental edema postexercise.

After confirming the diagnosis of CECS, each patient was subjected to a stress CT angiography (CTA) of the legs using a patented protocol to simulate the push off phase of the gait cycle.¹⁹ The scan was performed in a Siemens SOMATOM Definition AS scanner (Siemens Medical Solutions USA, Malvern, Pennsylvania). Before scanning, the patient was positioned using the MVP Flex (McGinley Education Innovations LLC, Casper, Wyoming). The patient was placed on the MVP Flex pad, and the hand grips were adjusted to provide mild tension at rest (Figure 1A). The patient's feet

TABLE 1. Population Characteristics (n = 284)	
Age, y	27.3 ± 1.3 (16-77)
Sex, male/female, no.	97/187
Both CECS and venous occlusion	91.5% (n = 260)
CECS alone	1.0% (n = 3)
Venous occlusion alone	7.4% (n = 21)
Unilateral involvement	6.7% (n = 19)
Bilateral involvement	93.3% (n = 265)

CECS, chronic exertional compartment syndrome.

were placed against the pressure plate. A test of positioning was performed by having the patient plantar flex against the pressure plate. A force of 100 to 140 pounds was required and noted on the pressure monitor (Figure 1B). This force range was developed based on the average vertical ground reaction force during the running cycle for an average patient.^{20–23} The patient held the plantar-flexed position within this pressure range for 60 seconds. The onset of symptoms was noted during the initial test. Adjustments in positioning were made as needed. After proper positioning, the patient released the hand grips and placed their feet against the MVP Flex pad at rest. A pressure reading of 0 pounds was confirmed on the monitor. Resting CTA images of the arterial and venous system of both legs were obtained to confirm normal resting

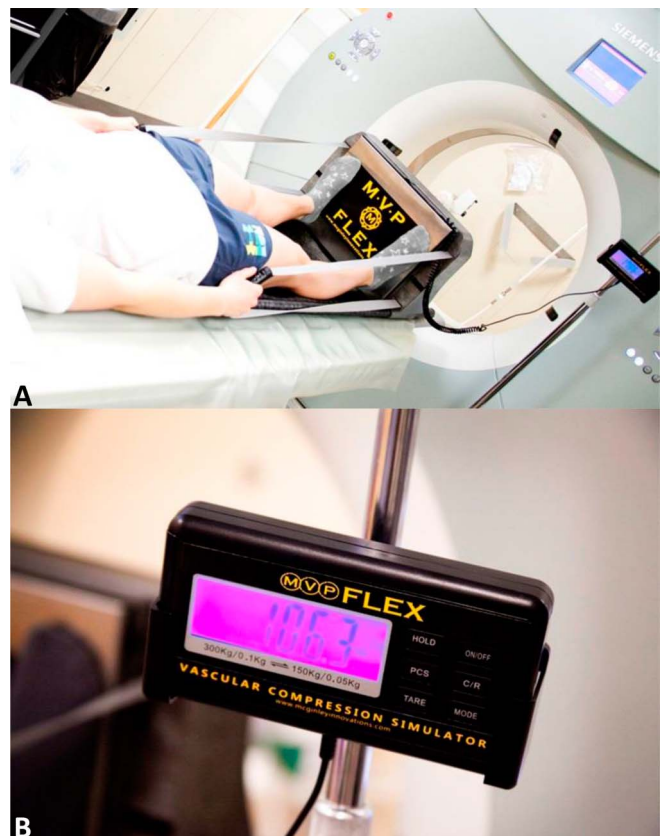

Figure 1. Patient positioning for CTA stress imaging. (A) The patient is positioned supine on the MVP Flex with the hand straps taut and feet plantar flexed against the pressure plate. B, Plantar flexion force generation was maintained between 100 and 140 pounds CTA, CT angiography.

anatomy and physiology. Resting CTAs were performed using an injection of 100cc of Omnipaque 240. Scan monitoring was used and scanning initiated when contrast was noted in the mid femoral artery. Arterial and venous phase images from the groin to the feet were acquired. After rest imaging, the patient was positioned in the MVP Flex device by grasping the hand grips and placing their feet against the pressure plate. An additional bolus of 100cc of Omnipaque 240 was injected, the patient plantar flexed against the plate once contrast was noted in the mid femoral artery. The patient generated 100 to 140 pounds of plantar flexion pressure and held the position for repeat CTA imaging of the arterial and venous system. Resting and stress images of the arterial and venous system were evaluated using cross-sectional images and 3-dimensional image reconstructions.

Rest images were evaluated for vessel patency, configuration of vascular anatomy, soft tissue abnormalities, osseous changes, and vessel opacification with contrast. The patency of the veins was evaluated to exclude deep venous thrombosis or chronic venous occlusion. The arteries were evaluated for patency, the presence of wall remodeling/thickening, or early atherosclerosis. The soft tissues were evaluated for muscle hernias or masses, including a Baker cyst, lipoma, or solid lesion. Acute injuries of the soft tissues were also excluded, including muscle strain or tendon injuries. The osseous structures were evaluated to exclude stress fractures or periosteal reaction. After excluding anatomic causes of lower leg pain, stress images were reviewed. The arterial system was evaluated for vascular compression including popliteal artery entrapment syndrome. Similarly, the venous system was evaluated to identify possible areas of venous compression with planar flexion against resistance.

A targeted, patented, botulinum toxin injection into the area of muscle compression was then performed in all 284 patients.¹⁹ One ninety-seven of the 284 patients were reevaluated posttreatment using stress CTA [average 20.7 weeks \pm 1.8 (95% CI)]. The remaining 87 patients were not reevaluated (81 patients had complete resolution of symptoms and 6 were lost to follow-up).

RESULTS

Demographics and results are summarized in Tables 1 and 2. Chronic exertional compartment syndrome was confirmed by history, physical examination, and stress MRI in 263 of the 284 patients included in this study. Of these 263 patients, 260 demonstrated both positive MRI findings of CECS and functional venous outflow obstruction. One hundred thirty-one patients previously underwent intracompartmental pressure measurements and 121 showed elevated pressures. Twenty-one patients displayed popliteal artery and/or vein entrapment without positive MRI findings. The patients described worsening symptoms with activity and relief of symptoms after cessation of activity. Nineteen patients demonstrated unilateral symptoms and 265 patients had bilateral symptoms. Nineteen patients had resting symptoms that worsened with exercise. No acute soft tissue injuries were identified. Ninety-one patients had at least one previous compartment fasciotomy for compartment syndrome without sustained relief. Eight patients had previous popliteal artery entrapment release surgery without relief of symptoms.

Venous phase rest imaging revealed a duplicated femoral vein at the level of the adductor canal in one patient. Six

TABLE 2. Posttreatment CTA Data (n = 197)*

Average time since treatment, wk	20.7 \pm 1.8 (4-75)
Reduced or resolved venous occlusion	78.7% \pm 5.7% (n = 155)
Reduced or resolved arterial occlusion	67.5% \pm 6.5% (n = 133)
<i>*Data given as mean \pm SE [95% CI] (range) unless otherwise noted. CTA, CT angiography.</i>	

patients demonstrated mild occlusion of the popliteal vein at rest, and 2 demonstrated moderate occlusion at rest. Arterial phase rest imaging showed moderate peripheral vascular disease in 3 patients. No patients demonstrated arterial occlusion at rest. Nineteen patients had small muscle hernias of the medial head of the gastrocnemius, 12 unilateral and 7 bilateral. One patient had a Baker cyst that extended along the fascial plane posteromedial to the medial head of the gastrocnemius muscle.

With stress imaging, 230 patients demonstrated functional popliteal artery entrapment syndrome (fPAES). In 223 of these 230 patients, compression was produced by the medial and lateral heads of the gastrocnemius muscle, with 60 also demonstrating some degree of compression by the popliteus and/or soleus muscles (Figure 2A, B). In addition, 3 patients had compression of the popliteal artery by the popliteus muscle, and 3 patients showed compression of the femoral artery in the adductor canal. One patient demonstrated compression of the posterior tibial artery.

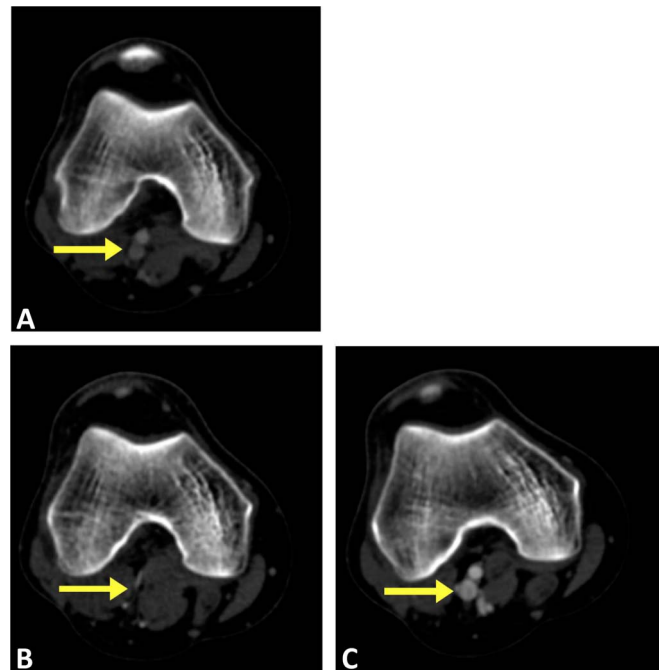


Figure 2. Axial CTA images of the popliteal artery and vein. A, Pre-treatment at rest demonstrates patency of the popliteal artery and vein, no variant anatomy, (B) pretreatment with active plantar flexion against resistance demonstrates complete compression of the popliteal vein and near complete compression of the popliteal artery, (C) 6 months after botulinum toxin treatment with active plantar flexion against resistance demonstrates no residual compression of the vascular structures. CTA, CT angiography.

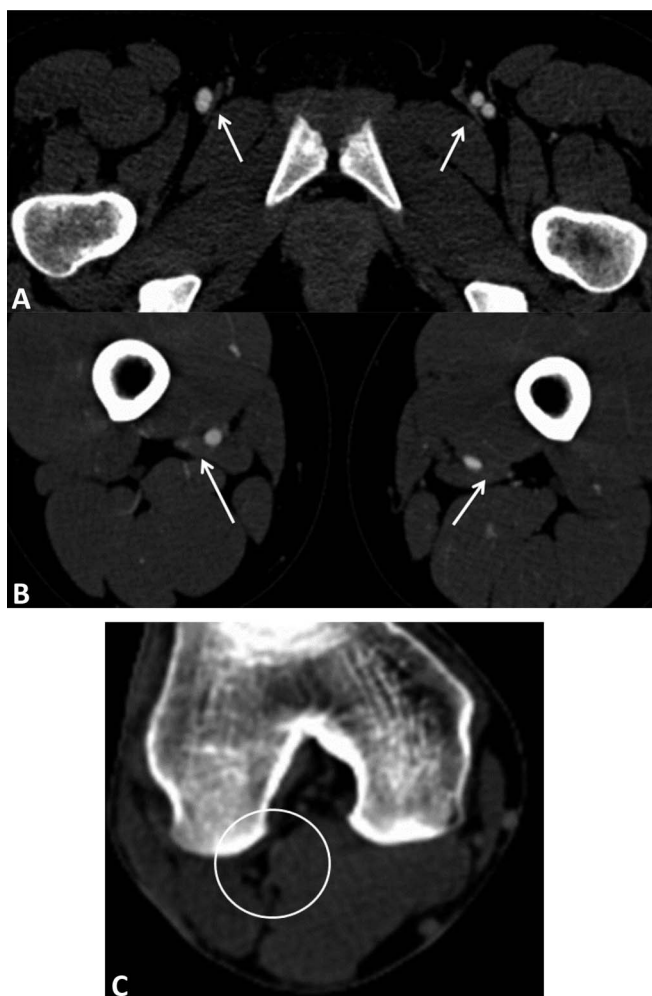


Figure 3. Location of venous compression varied among patients. A, Axial CTA images at the groin demonstrate femoral vein compression by the pectineus muscle (arrow). B, Axial CTA images at the level of the mid to distal femur demonstrate femoral vein compression in the adductor canal by the adductor longus muscle bilaterally (arrow) with mild compression of the femoral artery on the left. C, Axial CTA images at the level of the popliteal fossa demonstrate complete compression of the popliteal artery and vein by the medial and lateral head of the gastrocnemius muscle (circle). CTA, CT angiography.

In 277 patients, there were various locations of venous outflow obstruction due to functional muscle compression (Figure 3). One patient demonstrated compression of the femoral vein by the pectineus muscle (Figure 3A). Six patients had compression of the femoral vein in the adductor canal by the adductor longus muscle (Figure 3B). Two patients had compression of the posterior tibial vein, and 4 patients had compression exclusively in distal branch veins. Two hundred sixty-five patients had compression of the popliteal vein by the medial and lateral heads of the gastrocnemius muscle (Figure 3C) with 141 also demonstrating some degree of compression by the popliteus and/or soleus muscles.

A sonographic and CT-guided botulinum toxin type A injection (range 50-400U) was performed at the site of muscular compression. Three to 4 weeks after treatment, 227 of 284 patients [79.9% \pm 4.7% (95% CI)] described reduced or resolved symptoms with exercise. Twenty-two

patients were lost to follow-up, and 35 patients had persistent symptoms. Posttreatment imaging using the MVP Flex with stress CTA demonstrated resolved or markedly reduced venous outflow obstruction at injected sites in 155 of the 197 reimaged patients [78.7% \pm 5.7% (95% CI)] (Figure 2C). In 133 of the 197 patients [67.5% \pm 6.5% (95% CI)], there was complete resolution of arterial compression at an average of 20.7 \pm 1.8 weeks posttreatment. In patients with residual arterial compression, the severity of compression was reduced by 53.4%. In all the patients with unresolved symptoms, there were residual or new areas of venous outflow obstruction present at the time of repeat stress imaging.

DISCUSSION

Chronic exertional compartment syndrome can be a debilitating process affecting athletes of varying ages. Symptoms are insidious in onset and often progress with time.^{24,25} Pain related to CECS can cause athletes to discontinue competitive sports or seek surgical intervention. Chronic exertional compartment syndrome most often involves the anterior and lateral compartments.¹³ Some studies with older patients (mean age: 26.6 years) report a greater prevalence in men, but other studies with a younger population (mean age: 16.4) demonstrate a greater prevalence in women.^{13,26,27} Other studies report an even distribution between men and women.^{11,24,28} The cause of CECS has not previously been proven. Chronic exertional compartment syndrome develops when increased intramuscular pressure hinders blood flow resulting in transient ischemia.^{7,16,29} Other theories suggested in the literature as contributing to CECS include metabolic factors, muscle hypertrophy, fascial thickening, microtrauma, or myopathy.^{6,15,30,31} Our findings suggest the cause of CECS is venous outflow obstruction due to functional muscular compression.

Initial evaluation of patients with lower leg pain is centered on identifying the source of pain and eliminating other possible causes of the patients' symptoms. The standard diagnosis of CECS is based on invasive compartment pressure measurements at rest and after an exercise protocol.^{15,28,32,33} Several studies have attempted to diagnose CECS using noninvasive techniques including preexercise/postexercise MRI and 31 P-NMR.^{4,5,34-37} Ringler et al⁴ evaluated postexercise leg MRI scans in 79 patients suspected of having CECS. By evaluating the T2 signal intensity ratio, this study demonstrated excellent reliability and reproducibility in diagnosing CECS.

Treatment of CECS is limited. Initial management centers on conservative methods including physical therapy.³⁸ Most often, athletes fail conservative treatment and change/discontinue competitive sports. Other athletes seek surgical treatment through fasciotomies/fasciectomy to address the symptoms of CECS.^{18,30,38} After surgery, symptoms may return, several studies report a surgical success involving the anterior compartment of 80% to 100% and 50% to 65% for the deep posterior compartment.^{13,15,32} Symptom recurrence likely results from scar tissue and pseudo-compartment formation.³² Studies have shown up to 36% of patients have symptom recurrence after fasciotomy.^{13,16-18} Based on our findings, surgery likely addresses the symptoms of CECS related to elevated compartment pressures. Our data suggest that the cause of CECS, functional venous outflow obstruction, remains present in the patients with recurrent symptoms.

Of the 284 patients examined in this study, 260 [91.5% \pm 3.23% (95% CI)] demonstrated both MRI findings of CECS and CTA findings of functional venous outflow obstruction. Based on the observation that venous obstruction is present in most patients with CECS, we believe that at the earliest stages of calf pain, the primary mechanism is functional venous outflow obstruction beyond the patient's normal capacity to accommodate. Based on Starling forces at the capillary level, arterial inflow is elevated because of exercise yet venous outflow is obstructed beyond normal levels of compensation. This results in elevated hydrostatic pressures and increased fluid transudation across the capillaries. This will then cause elevated compartment pressures and edema as demonstrated on MRI. As the patient continues to exercise, the calf muscles further enlarge, worsening the severity of functional venous outflow obstruction. Because average arterial pressure is higher, arteries are initially resistant to compression in early stages of disease. However, as functional compression continues to worsen over time, this process progresses to functional compression of the associated artery. Arterial involvement leads to symptoms of transient ischemia, including numbness, tingling, and discoloration in the feet and toes. Because nerves also travel in bundles with veins and arteries, there is likely also nerve compression occurring and contributing to symptoms. This finding suggests that CECS and fPAES exist not as separate diseases but on a continuum of disease based on severity of functional compression.

After hypothesizing the cause of CECS as venous outflow obstruction, all patients underwent an imaging-guided botulinum toxin injection of the affected area. At an average of 20.7 ± 1.8 weeks after treatment, repeat stress CTA was performed in 197 patients. Of those, 155 patients [78.7% \pm 5.7% (95% CI)] showed normalization or significant improvement of venous patency at the site of botulinum toxin injection. This demonstrates the effectiveness of targeted botulinum toxin at relieving muscle-induced venous occlusion. Furthermore, 227 of 284 patients [79.9% \pm 4.7% (95% CI)] described reduced or resolved symptoms with exercise 3 to 4 weeks after treatment. Residual venous occlusion at sites not treated or the emergence of new compression sites was likely responsible for the persistence or return of symptoms. The significant resolution of pain after relief of venous occlusion provides further evidence that CECS is caused by functional venous outflow obstruction.

Because of the retrospective design of this study, potential limitations exist. Primarily, patients included in this study were not randomly selected. However, the demographics of our patient sample align with other CECS studies in age and sex distributions, indicating our sample likely is representative of the CECS population.^{6,13,17,26,27} Next, repeat MRIs were not performed after botulinum toxin treatment. Another potential limitation of this study was false-positive or false-negative CTA findings in patients with leg pain. To limit this, CECS was first confirmed with history, physician examination, and use of preexercise/postexercise MRI. In addition, the force generated using the MVP Flex was limited to 100 to 140 pounds as to not over engage the calf muscle. Over engagement of the calf musculature may result in false-positive findings of venous outflow obstruction. Another potential limitation would be in replicating positioning on pretreatment and posttreatment studies. This again was addressed by maintaining pressure generation on the MVP Flex between 100 and 140 pounds. On

follow-up scans, care was taken to reproduce the force generated within 5 lbs. of the baseline study.

The findings presented in our study demonstrate a cause of CECS and a noninvasive diagnostic protocol to evaluate symptomatic patients. The pressures generated using the MVP Flex reproduce moderate activation of the calf muscles with plantar flexion. This technique reproduced symptoms of CECS in all patients. Identifying the cause of CECS as venous outflow obstruction enables safe and effective nonsurgical treatments that precisely target the site of abnormality.

References

1. Detmer D, Sharpe K, Sufit R, et al. Chronic compartment syndrome: diagnosis, management, and outcomes. *Am J Sports Med.* 1985;13:162–170.
2. Pedowitz RA, Hargens AR, Mubarak SJ, et al. Modified criteria for the objective diagnosis of chronic compartment syndrome of the leg. *Am J Sports Med.* 1990;18:35–40.
3. Pupka A, Bogdan J, Lepiesza A, et al. Sport related compression syndromes—review of the literature. *Medicina Sportiva.* 2010;14:83–89.
4. Verleisdonk EJ, van Gils A, van der Werken C. The diagnostic value of MRI scans for the diagnosis of chronic exertional compartment syndrome of the lower leg. *Skeletal Radiol.* 2001;30:321–325.
5. Ringler MD, Litwiller DV, Felmlee JP, et al. MRI accurately detects chronic exertional compartment syndrome: a validation study. *Skeletal Radiol.* 2013;42:385–392.
6. Lecocq J, Isner-Horobeti ME, Dupeyron A, et al. Exertional compartment syndrome. *Ann Readapt Med Phys.* 2004;47:334–345.
7. Styf J. Definitions and terminology. Etiology and pathogenesis of chronic compartment syndrome. In: Styf J, ed. *Compartment Syndromes: Diagnosis, Treatment, and Complications.* Boca Raton, FL: CRC Press LLC; 2004.
8. Black KP, Taylor DE. Current concepts in the treatment of common compartment syndromes in athletes. *Sports Med.* 1993;15:408–418.
9. Soderberg TA. Bilateral chronic compartment syndrome in the forearm and the hand. *J Bone Joint Surg Br.* 1996;78:780–782.
10. Garcia-Mata S, Hidalgo-Overjero A, Martinez-Grande M. Chronic exertional compartment syndrome of the legs in adolescents. *J Pediatr Orthop.* 2001;21:32–34.
11. Waterman BR, Liu J, Newcomb R, et al. Risk factors for chronic exertional compartment syndrome in a physically active military population. *Am J Sports Med.* 2013;41:2545–2549.
12. Reneman RS. The anterior and the lateral compartment syndrome of the leg due to intensive use of muscles. *Clin Orthop Relat Res.* 1975;Nov-Dec:69–80.
13. Campano D, Robaina JA, Kusezov N, Dunn JC, Waterman BR. Surgical management for chronic exertional compartment syndrome of the leg: a systematic review of the literature. *Arthroscopy.* 2016;32:1478–1486.
14. Howard JL, Mohtadi NG, Wiley JP. Evaluation of outcomes in patients following surgical treatment of chronic exertional compartment syndrome in the leg. *Clin J Sport Med.* 2000;10:176–184.
15. Fraipont MJ, Adamson GJ. Chronic exertional compartment syndrome. *J Am Acad Ortho Surg.* 2003;11:268–276.
16. Schubert AG. Exertional compartment syndrome: review of the literature and proposed rehabilitation guidelines following surgical release. *Int J Sports Phys Ther.* 2011;6:126–141.
17. Slimmon D, Bennell K, Brukner P, et al. Long-term outcome of fasciotomy with partial fasciectomy for chronic exertional compartment syndrome of the lower leg. *Am J Sports Med.* 2002;30:581–588.
18. Wittstein JC, Moorman CT, III, Levin LS. Endoscopic compartment release for chronic exertional compartment syndrome: surgical technique and results. *Am J Sports Med.* 2010;38:1661–1666.
19. McGinley J. inventor. Method for treating and confirming diagnosis of exertional compartment syndrome. *U.S. Patent No. 9,226,954 B2.* January 5, 2016.
20. Bobbert MF, Schamhardt HC, Nigg BM. Calculation of vertical ground reaction force estimates during running from positional data. *J Biomech.* 1991;24:12.
21. Kyröläinen H, Avela J, Komi PV. Changes in muscle activity with increasing running speed. *J Sports Sci.* 2005;23:1101–1109.
22. Nilsson J, Thorstensson A. Ground reaction forces at different speeds of human walking and running. *Acta Physiol Scand.* 1989;136:217–227.

23. Kluitenberg B, Bredeweg SW, Zijlstra S, et al. Comparison of vertical ground reaction forces during overground and treadmill running. A validation study. *BMC Musculoskelet Disord.* 2012;13:235.
24. Birtles DB, Minden D, Wickes SJ, et al. Chronic exertional compartment syndrome: muscle changes with isometric exercise. *Med Sci Sports Exerc.* 2002;34:1900–1906.
25. Blackman PG. A review of chronic exertional compartment syndrome in the lower leg. *Med Sci Sports Exerc.* 2000;32:S4–S10.
26. Beck JJ, Tepolt FA, Miller PE, Micheli LJ, Kocher MS. Surgical treatment of chronic exertional compartment syndrome in pediatric patients. *Am J Sports Med.* 2016;44:2644.
27. Davis DE, Raikin S, Garras DN, Vitanzo P, Labrador H, Espandar R. Characteristics of patients with chronic exertional compartment syndrome. *Foot Ankle Int.* 2013;34:1349.
28. Shah SN, Miller BS, Kuhn JE. Chronic exertional compartment syndrome. *Am J Ortho.* 2004;33:335–341.
29. Mohler LR, Styf JR, Pedowitz RA, Hargens AR, Gershuni DH. Intramuscular deoxygenation during exercise in patients who have chronic anterior compartment syndrome of the leg. *J Bone Joint Surg Am.* 1997;79:844–849.
30. Hutchinson MR, Lloyd Ireland M. Common compartment syndromes in athletes: treatment and rehabilitation. *Sports Med.* 1994;17:200–208.
31. Turnipseed WD, Hurschler C, Vanderby R, Jr. The effects of elevated compartment pressure on tibial arteriovenous flow and relationship of mechanical and biochemical characteristics of fascia to genesis of chronic anterior compartment syndrome. *J Vasc Surg.* 1995;21:810–816.
32. Brennan FH, Jr, Kane SF. Diagnosis, treatment options, and rehabilitation of chronic lower leg exertional compartment syndrome. *Curr Sport Med Rep.* 2003;2:247–250.
33. Gill CS, Halstead ME, Matava MJ. Chronic exertional compartment syndrome of the leg in athletes: evaluation and management. *Physician and Sportsmed.* 2010;38:1–7.
34. Amendola A, Rorabeck CH, Vellett D, et al. The use of magnetic resonance imaging in exertional compartment syndromes. *Am J Sports Med.* 1990;18:29–34.
35. Litwiller DV, Amrami KK, Dahm DL, et al. Chronic exertional compartment syndrome of the lower extremities: improved screening using a novel dual birdcage coil and in-scanner exercised protocol. *Skeletal Radiol.* 2007;36:10133–11075.
36. Van den Brand JG, Nelson T, Verleisdonk EJ, et al. The diagnostic value of intracompartmental pressure measurement, magnetic resonance imaging, and near-infrared spectroscopy in chronic exertional compartment syndrome: a prospective study in 50 patients. *Am J Sports Med.* 2005;33:699–704.
37. Balduini FC, Shenton DW, O'Connor KH, et al. Chronic exertional compartment syndrome: correlation of compartment pressure and muscle ischemia utilizing 31P-NMR spectroscopy. *Clin Sport Med.* 1993;12:151–165.
38. Buerba RA, Fretes NF, Devana SK, Beck JJ. Chronic exertional compartment syndrome: current management strategies. *Open Access J Sports Med.* 2019;10:71–79.